

Advanced Airway Management: Percutaneous Cricothyrotomy

2011 Georgia Office of EMS Updates



EMT-Paramedic to Paramedic Update



Objectives

- Indications and Contraindication
- Anatomical Landmarks
- Predicting a Difficult Cricothyrotomy
- Percutaneous Cricothyrotomy
 - Modified Seldinger Technique
 - Cook® Melker Emergency Cricothyrotomy Catheter
 - Direct Airway Placement Devices
 - Nu-Trache®, QuickTrach®, Pertrach®
- Retrograde Intubation



Indications

- Airway Management Failure
 - ▶ DEATH OCCURS FROM **FAILURE TO VENTILATE**; NOT FAILURE TO INTUBATE! ◀
 - When traditional methods of establishing oxygenation and ventilation have been unsuccessful
 - Basic airway maneuvers/adjuncts with a bag-valve-mask(BVM)
 - Jaw-Thrust, Head-Tilt/Chin-Lift, Oropharyngeal Airway (OPA), Nasopharyngeal Airways (NPA)
 - Endotracheal Intubation
 - Orotracheal, Nasotracheal, Digital, Video Laryngoscopy
 - Blind Insertion Airway Devices (BIAD)
 - CombiTube®, King LT™, Cobra-PLA™, Laryngeal Mask Airway (LMA)



Indications

- Upper Airway Obstruction
 - Epiglottitis
 - Severe Anaphylaxis
 - Foreign body airway obstruction (FBAO)
 - Thermal injuries resulting in laryngeal edema
 - Massive facial injuries resulting in airway distortion



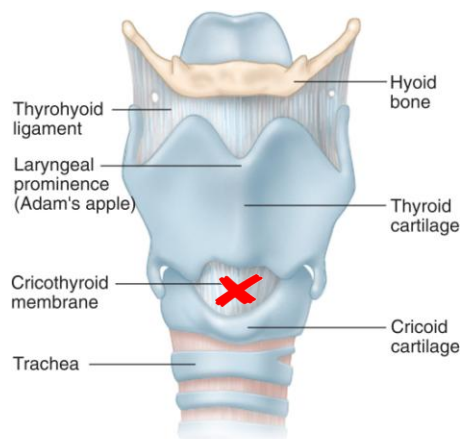
Contraindications

- Pediatrics (children younger than 8 years old)
 - Cricothyrotomy is extremely difficult, due to small, pliable larynx
 - Needle cricothyrotomy (transtracheal jet ventilation) is the preferred method for pediatric patients
- Inability to identify anatomical landmarks
 - Redundant tissue (short, fat necks)
 - Laryngeal trauma
 - Tumors/Hematomas
 - Scar tissue



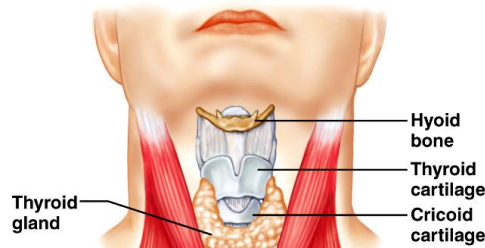
Anatomical Landmarks

- The cricothyroid membrane is the access site for emergency cricothyrotomy, regardless of the technique utilized
- Locate the laryngeal prominence (Adam's apple)
- The cricothyroid membrane is the soft depression between the hard thyroid cartilage and the hard cricoid cartilage



Anatomical Landmarks

- The thyroid gland is highly vascular and must be avoided during the procedure.
- Hemorrhage resulting from injury to the thyroid gland will decrease probability of success



Predicting a Difficult Cricothyrotomy

- The mnemonic SHORT may be utilized to gauge the difficulty of a cricothyrotomy
 - **S**urgery-prior surgical procedures may distort anatomy
 - **H**ematoma-may be traumatic, postoperative, or infectious abscess
 - **O**besity-redundant tissue may impair landmark identification
 - **R**adiation-scar tissue from therapy may distort anatomy
 - **T**umor-may impair landmark identification or result in bleeding

Cricothyrotomy

- There are several types of cricothyrotomies
 - Open Cricothyrotomy
 - Involves making an incision through the cricothyroid membrane with a scalpel and placing an ET tube or tracheostomy tube.
 - **OPEN CRICOTHYROTOMY IS NOT WITHIN THE PARAMEDIC SCOPE OF PRACTICE IN GEORGIA**
 - **GEORGIA PARAMEDICS MAY NOT MAKE A SURGICAL INCISION THROUGH THE CRICOTHYROID MEMBRANE**
 - Percutaneous Cricothyrotomy
 - Involves utilizing a needle and introducer/dilator to pierce through the cricothyroid membrane

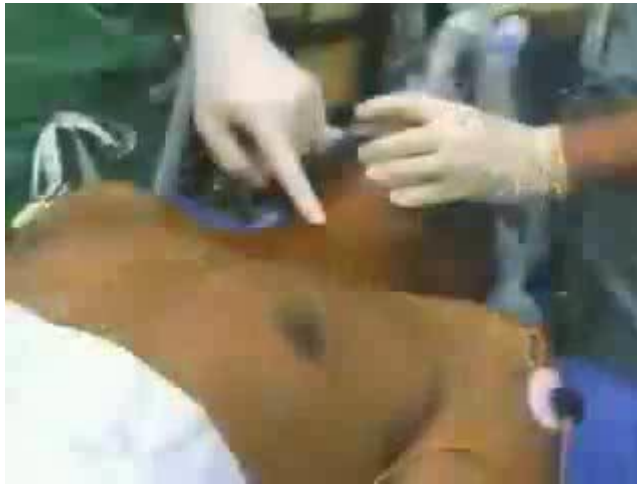

Percutaneous Cricothyrotomy

- Modified Seldinger Technique (*using a guide wire*)
 - A scalpel may be used to make a **skin incision** above the cricothyroid membrane.
 - A needle is used to penetrate the cricothyroid membrane so that a guide wire may be introduced into the trachea.
 - Once the needle is removed, the dilator-catheter assembly is fed over the wire and directed toward the cricothyroid membrane.
 - The dilator will gradually increase the opening so that the catheter may be placed.



Percutaneous Cricothyrotomy



Seldinger Technique



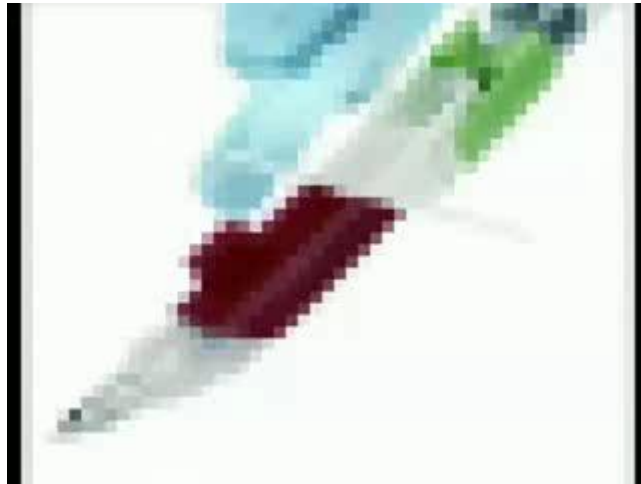Percutaneous Cricothyrotomy

- Commercial airway placement devices
 - Nu-Trache®, QuickTrach®, Pertrach®
 - These devices do not use a Seldinger technique
 - They function as both an introducer and an airway

NOTE: The Pertrach® may also require a scalpel to make a ***skin incision*** above the cricothyroid membrane



Percutaneous Cricothyrotomy



QuickTrach®



Percutaneous Cricothyrotomy

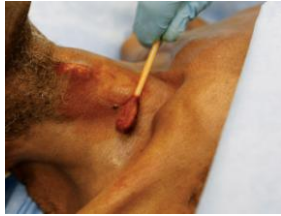Preparation and Use

Pertrach®

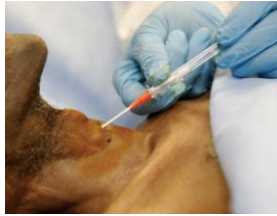

Retrograde Intubation (1 of 3)

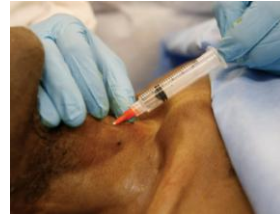- If laryngoscopic intubation is unsuccessful, the technique of retrograde intubation may be utilized.



Place the patient supine and cleanse the anterior part of the neck.



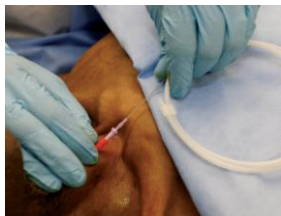Puncture the cricothyroid membrane.



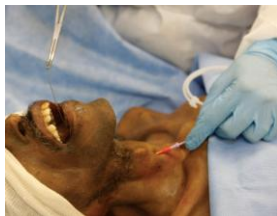Identify the tracheal lumen by aspirating the syringe attached to the needle.



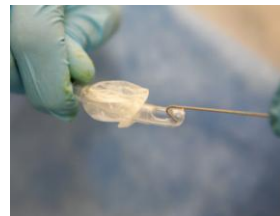Retrograde Intubation (2 of 3)



Pass the 70-cm guide wire through the catheter until it appears in the oropharynx, mouth, or one of the nares.



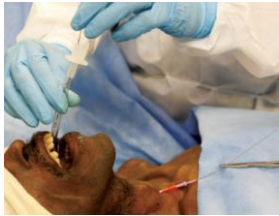If guide wire is in the oropharynx, grasp it with a clamp and pull the wire partially out of the mouth.



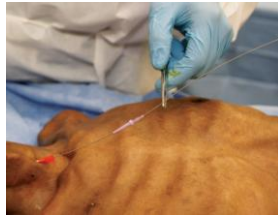Insert the guide wire emerging from the mouth through Murphy's eye, and pass it through the lumen of the ET tube.



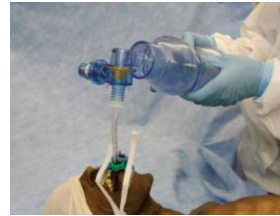Retrograde Intubation (3 of 3)



Advance the ET tube into the trachea. Auscultate the chest bilaterally and over the epigastrium.



Once tube placement is confirmed, remove the guide wire by pulling on the distal end.



Secure the ET tube in place and ventilate.



References

- Walls, R., & Murphy, M. (2008). *Manual of Emergency Airway Management* (3rd ed.). Pennsylvania: Lippincott Williams & Wilkins.
- *AAOS Critical Care Transport*. (2011). Massachusetts: Jones & Bartlett Publishing.



Summary

- All of the advanced airway procedures presented within this update are highly invasive.
- Continual training and competency evaluation is imperative to achieve successful airway management.
- All of these procedures are acceptable according to The State of Georgia Paramedic Scope of Practice.
- However, local medical direction may disallow any or all of these advanced procedures.